



Endovascular Management of Central Venous Occlusion Related to Hemodialysis

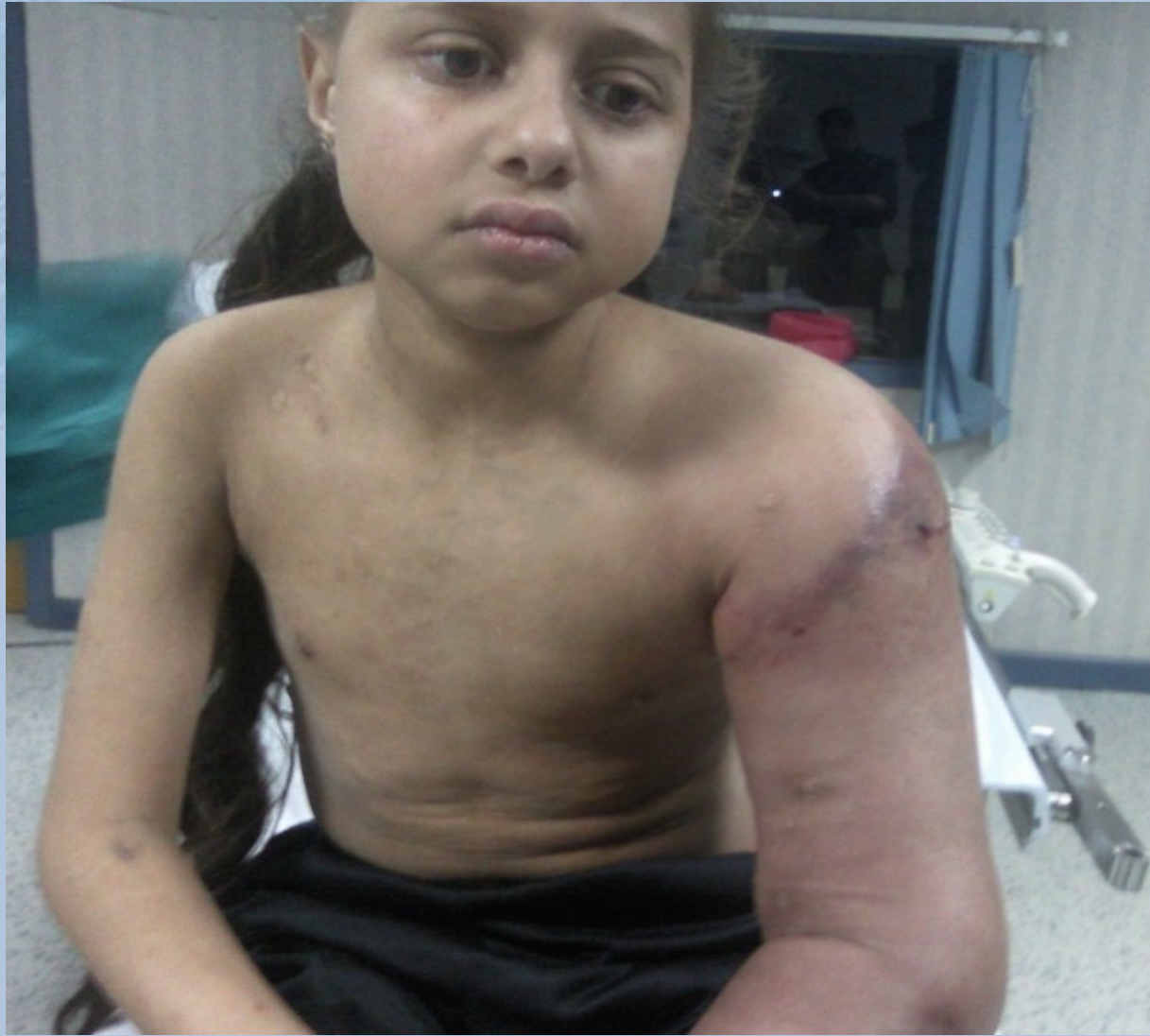Amr Aborahma, MD.
Tanta University

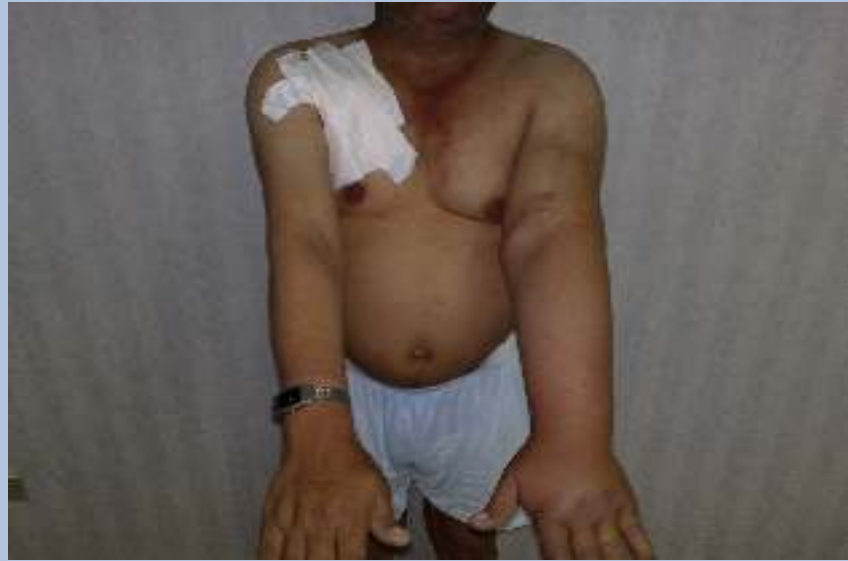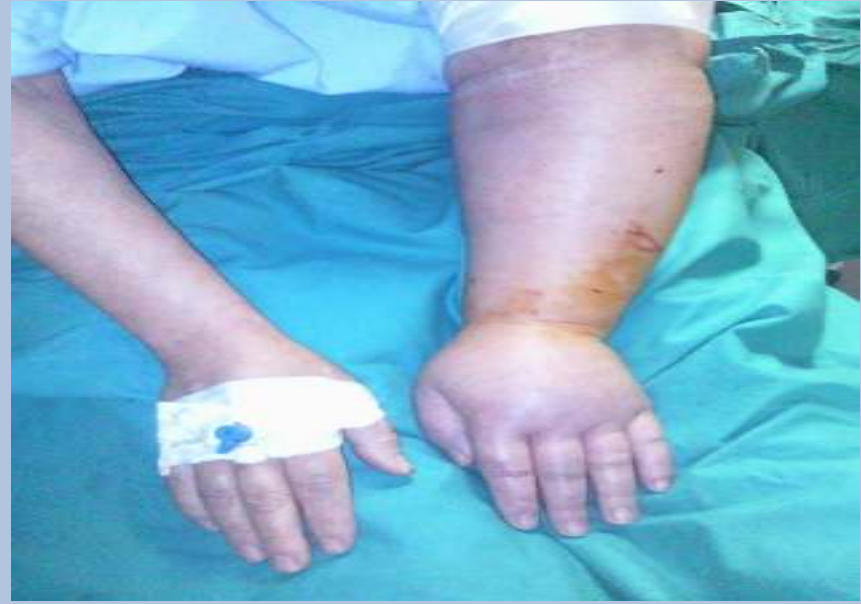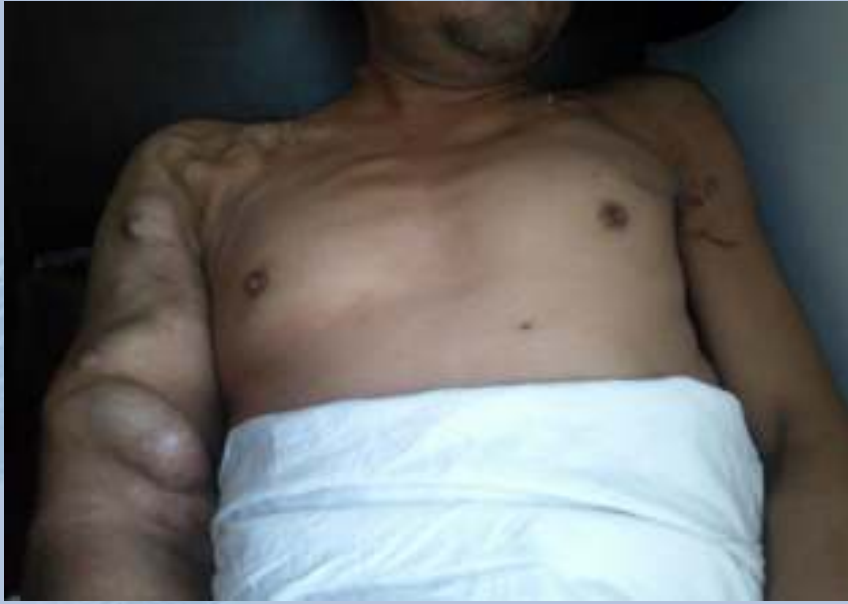A Challenge



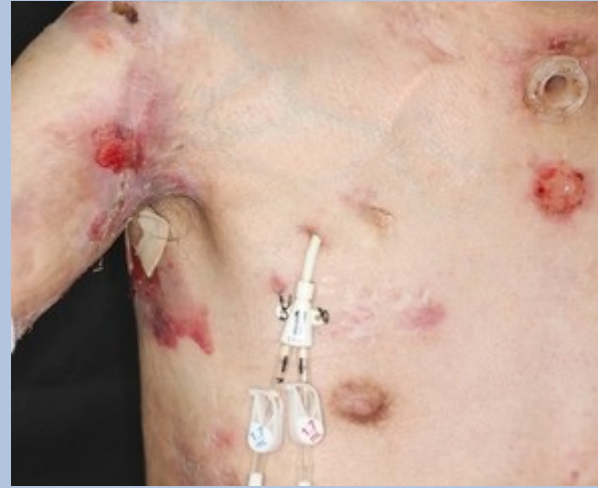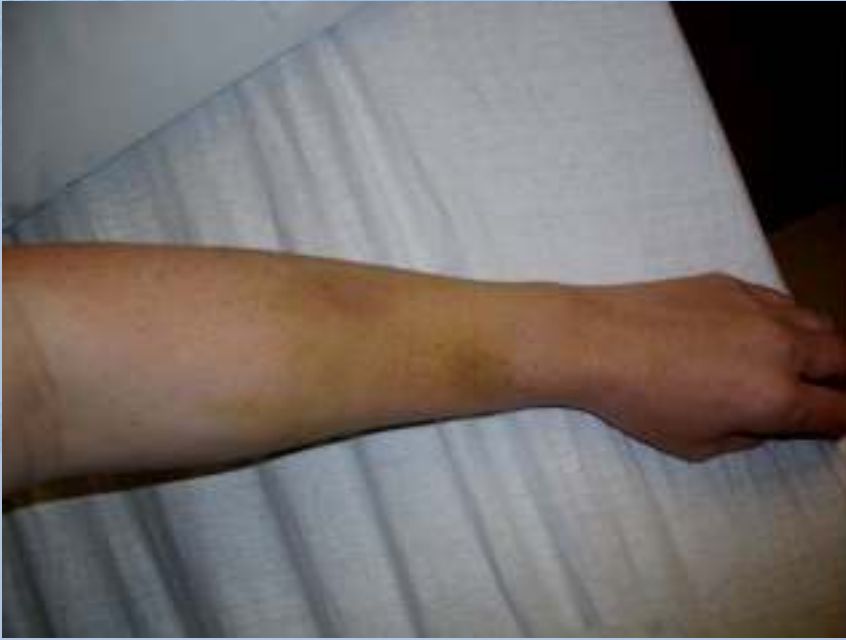Why it is challenging?

A
Matter
of
Life and
Death

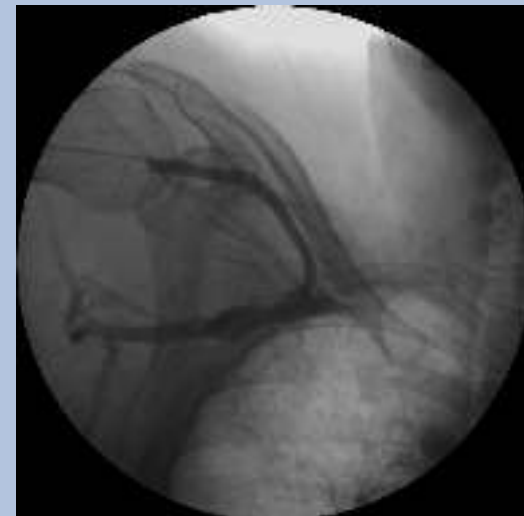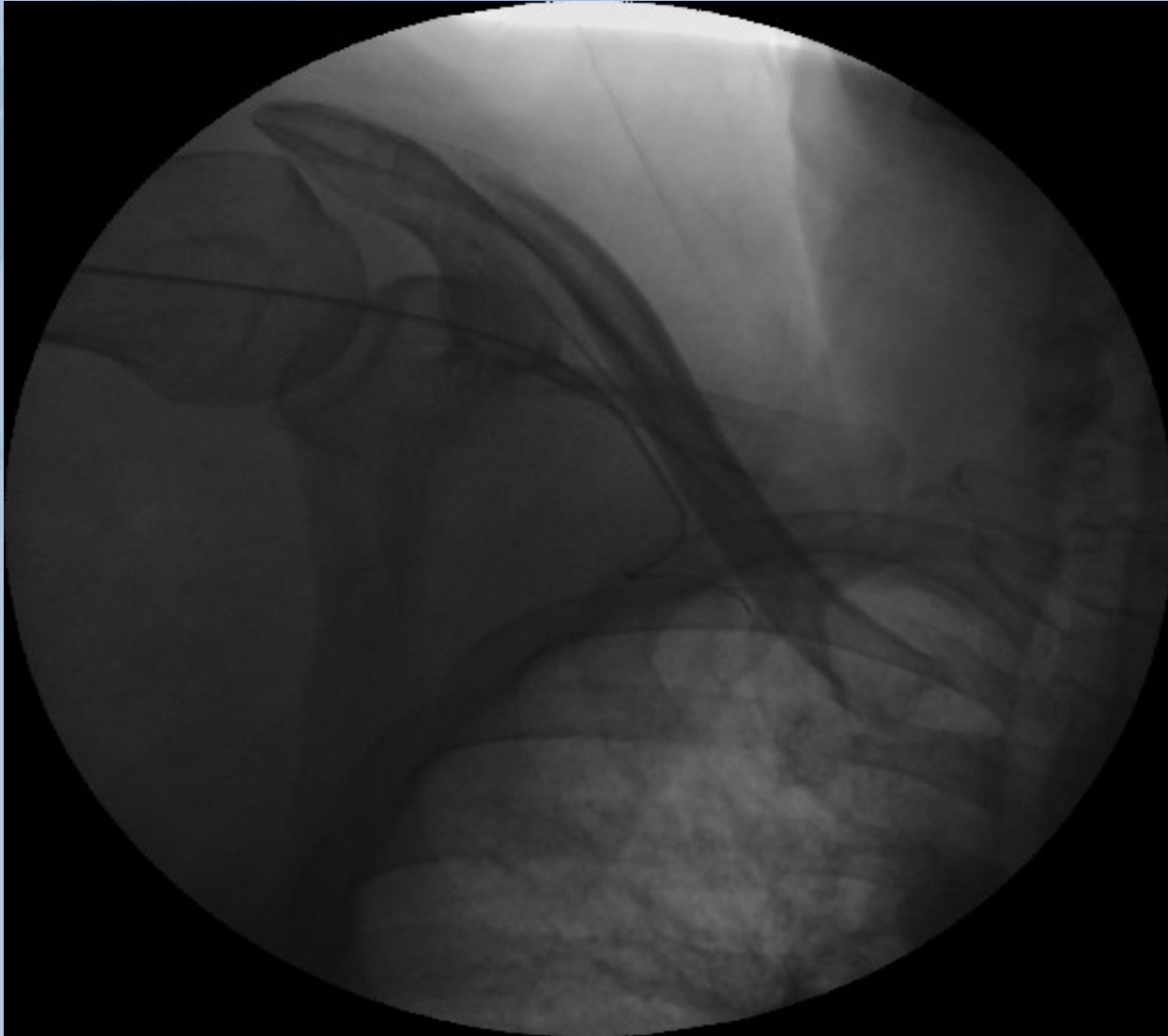



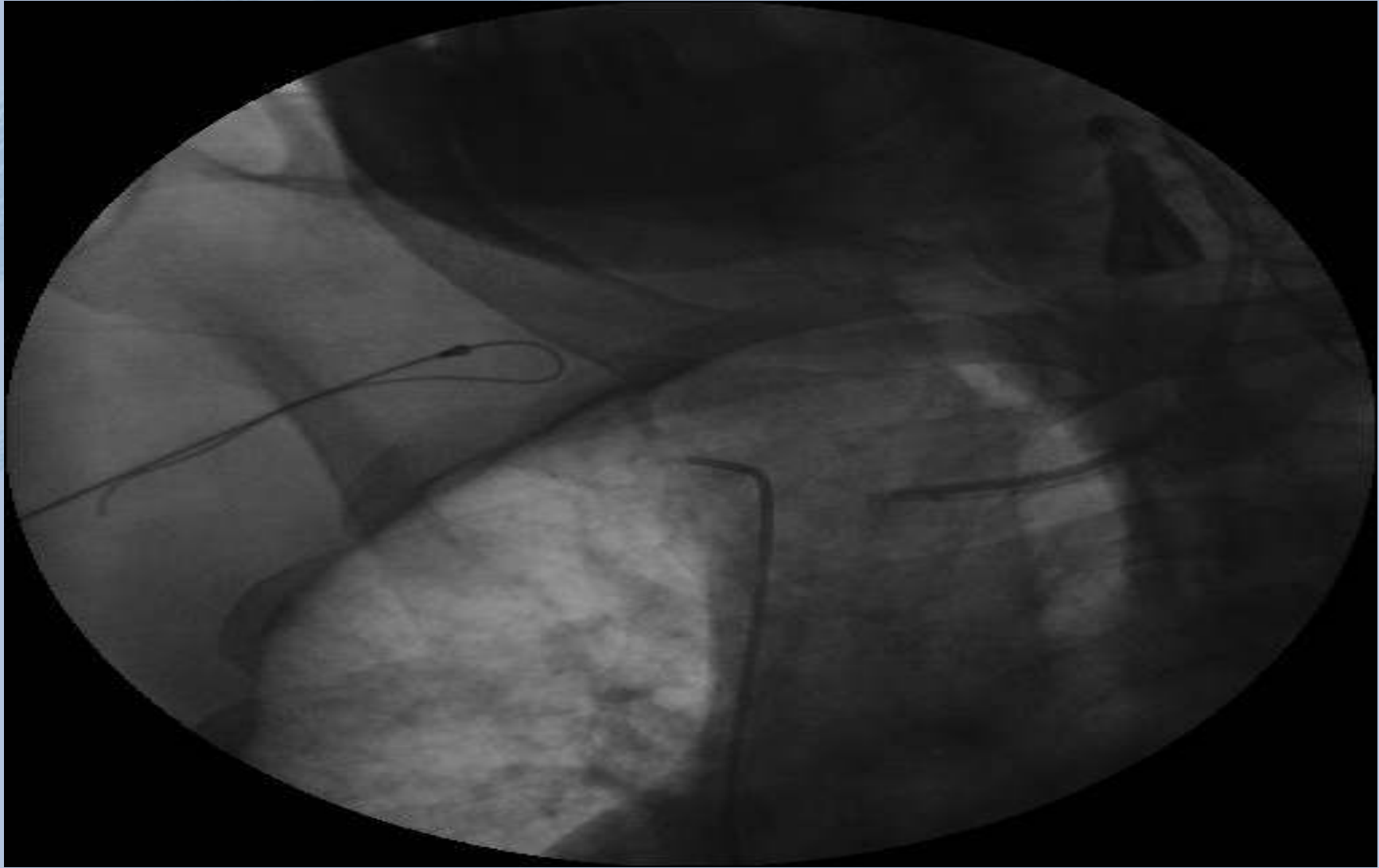
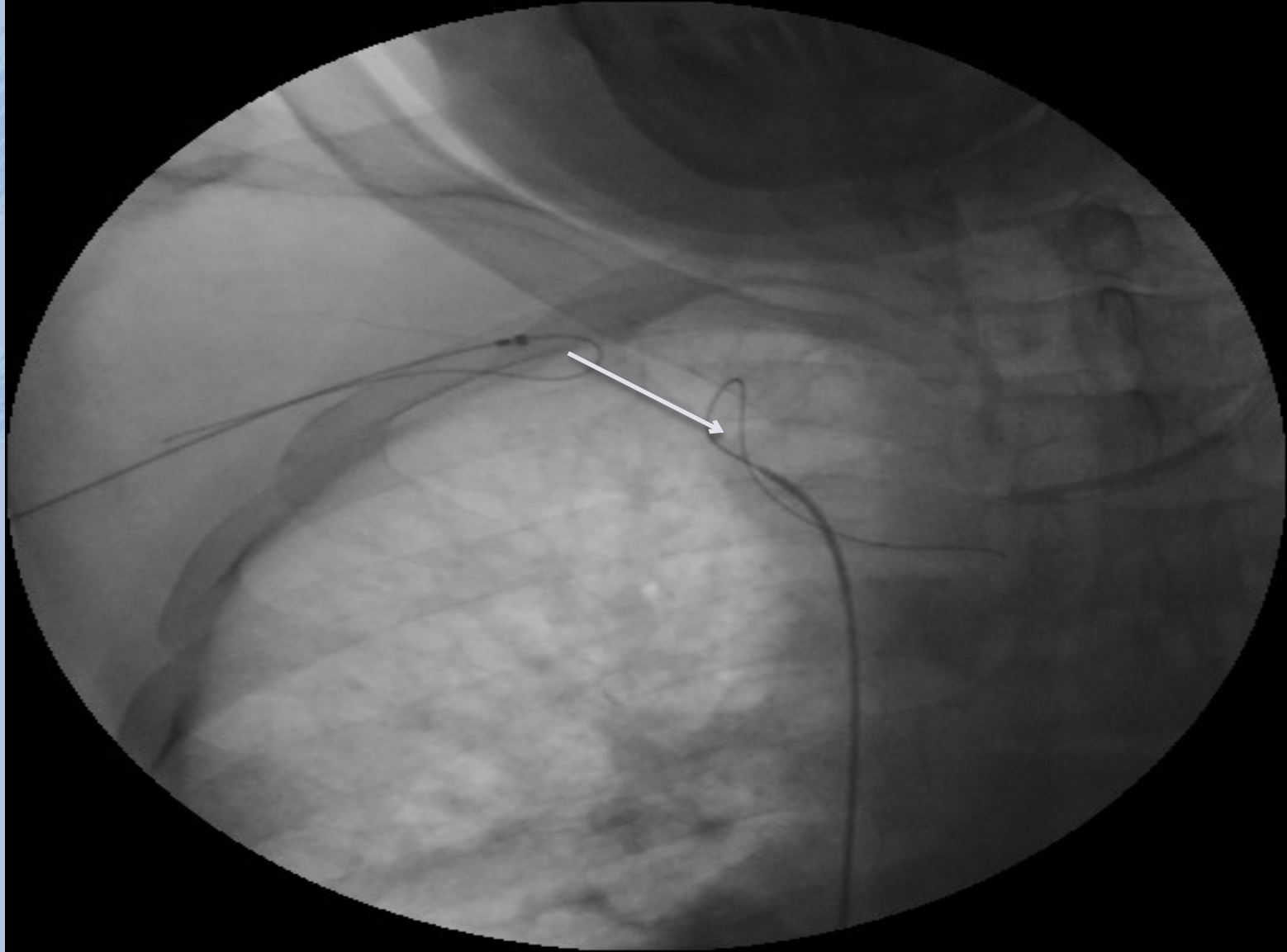
Why it is challenging?



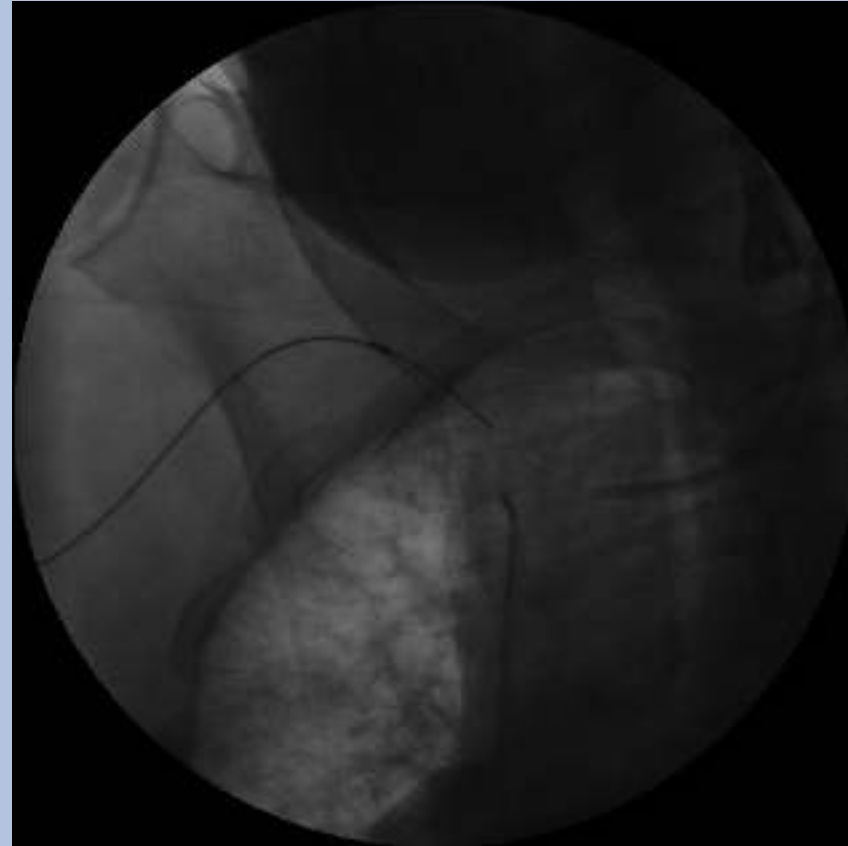
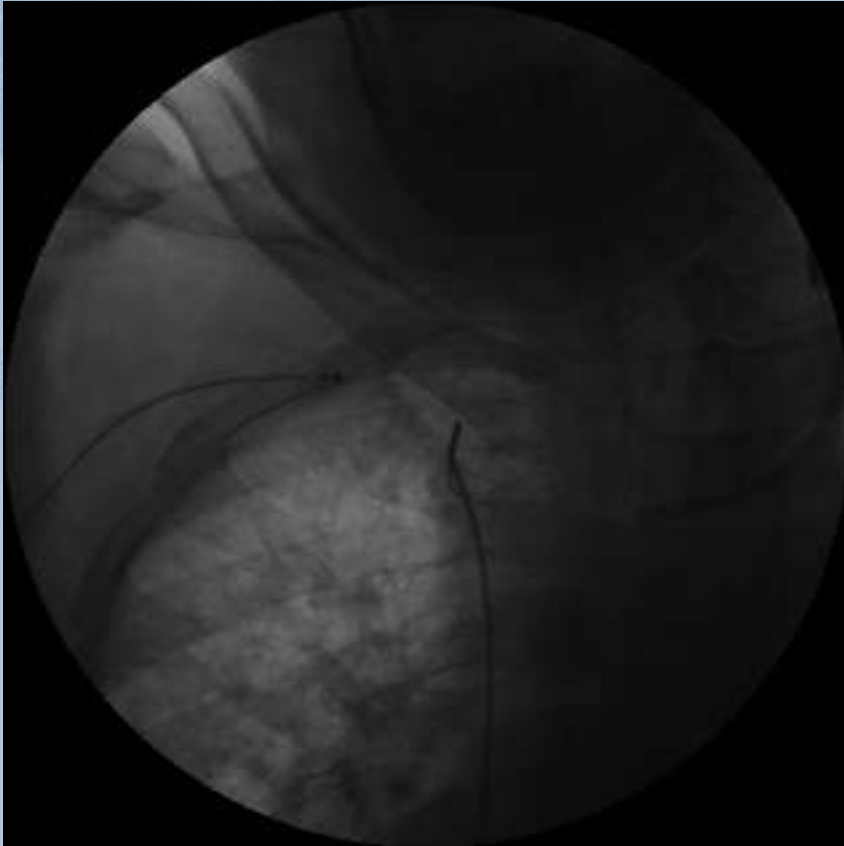
Crossing is challenging?

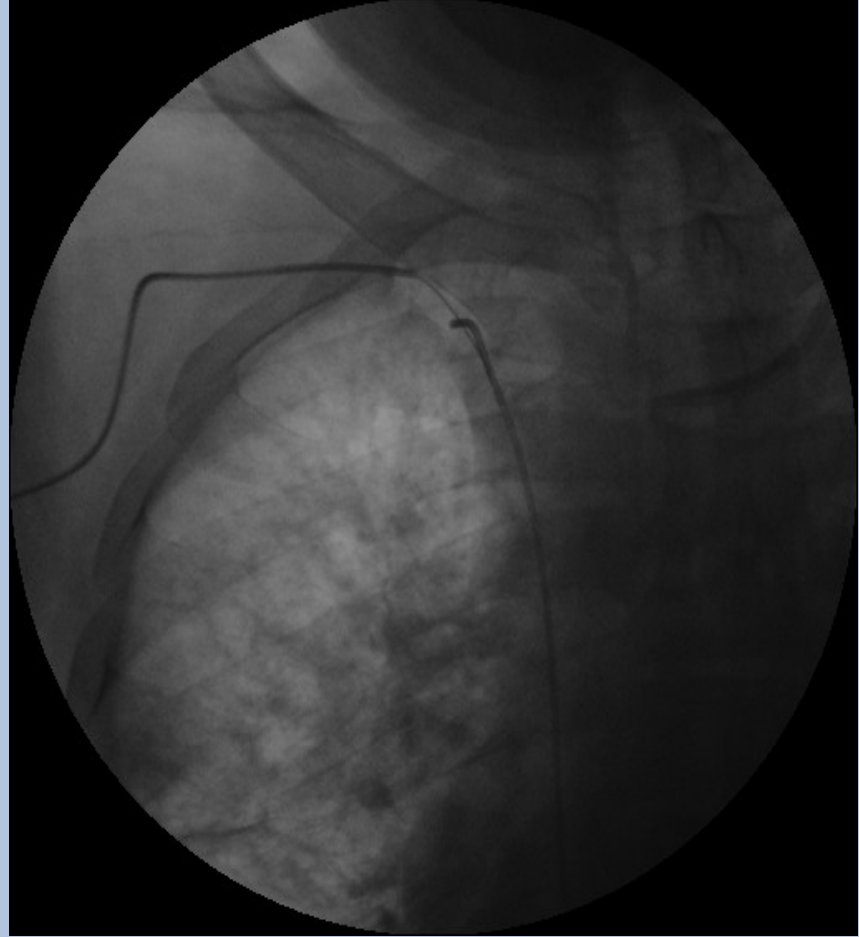
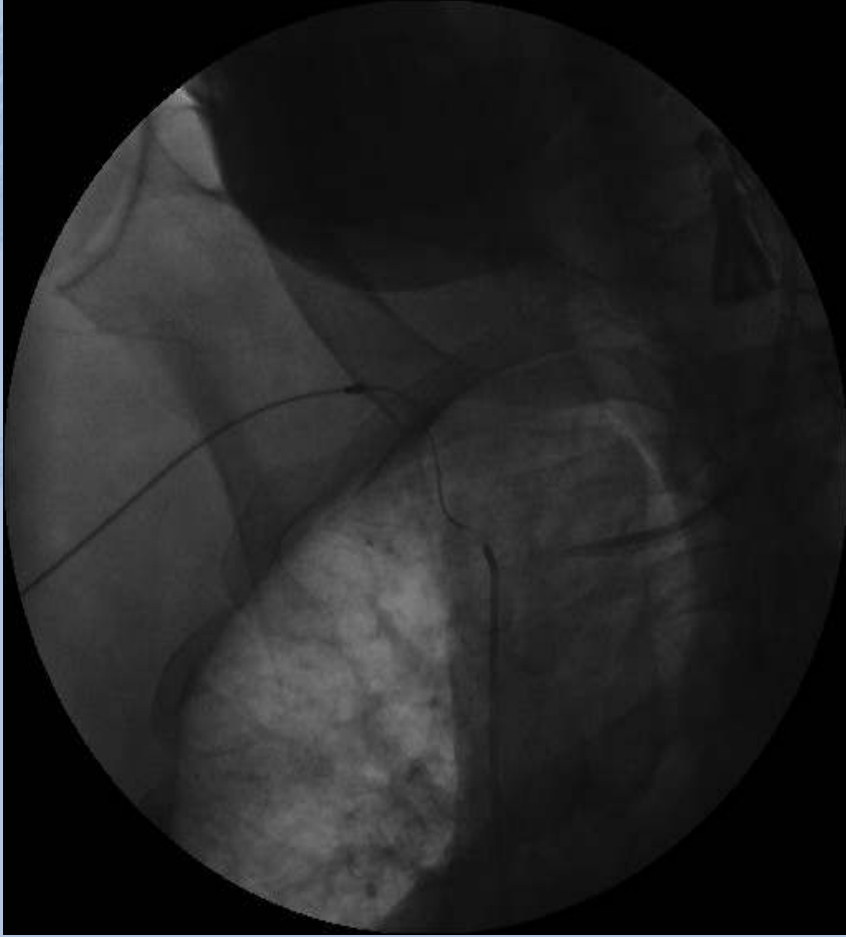




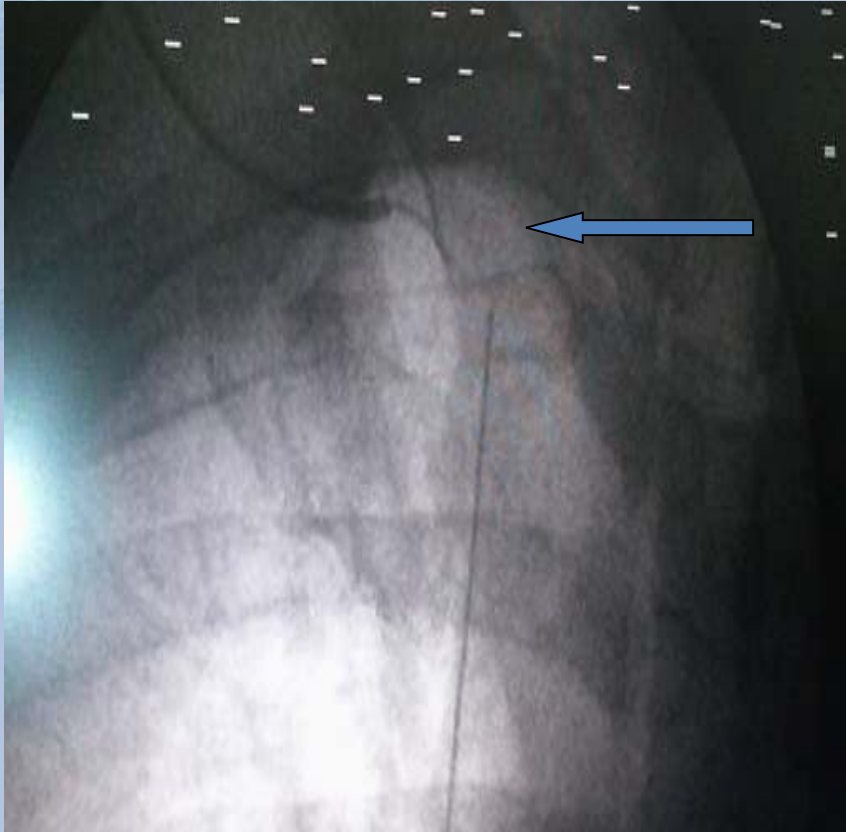


Sharp Recanalization

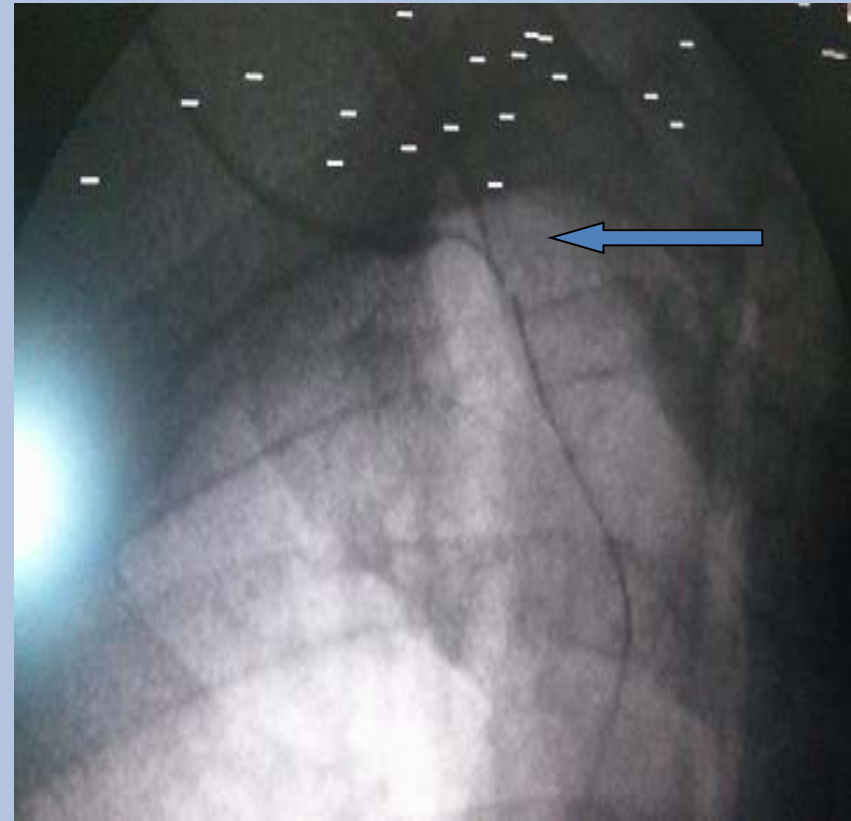




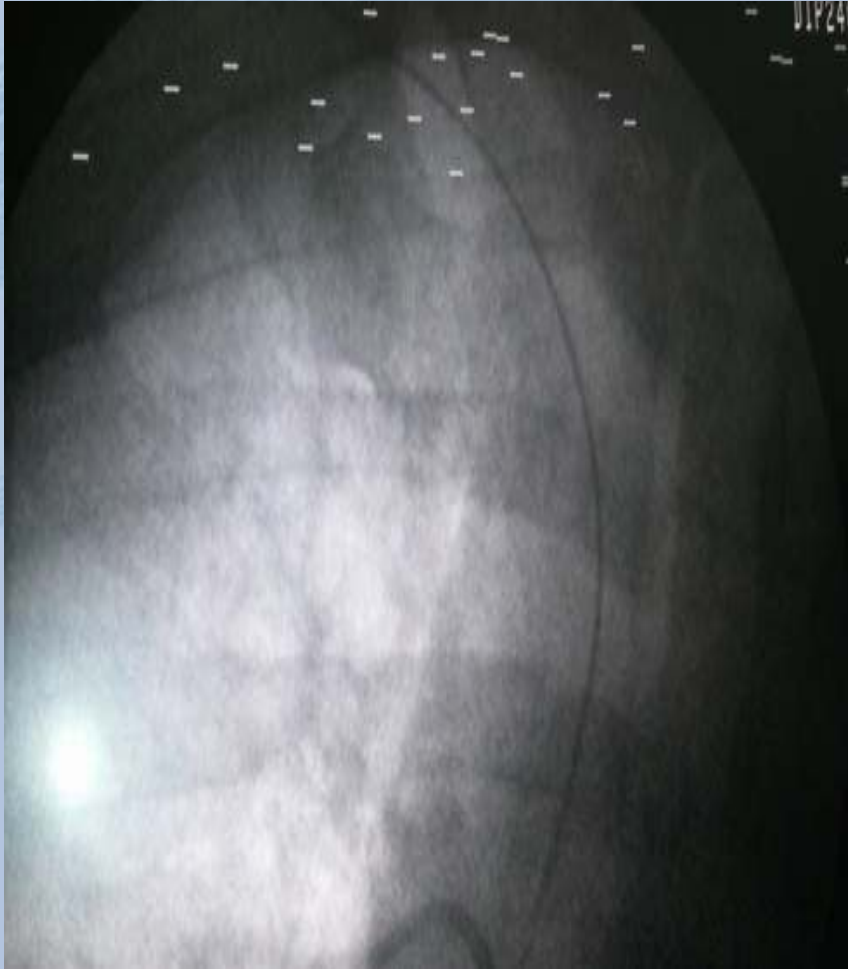A case of complete subclavian vein occlusion successfully recanalised through combined approach



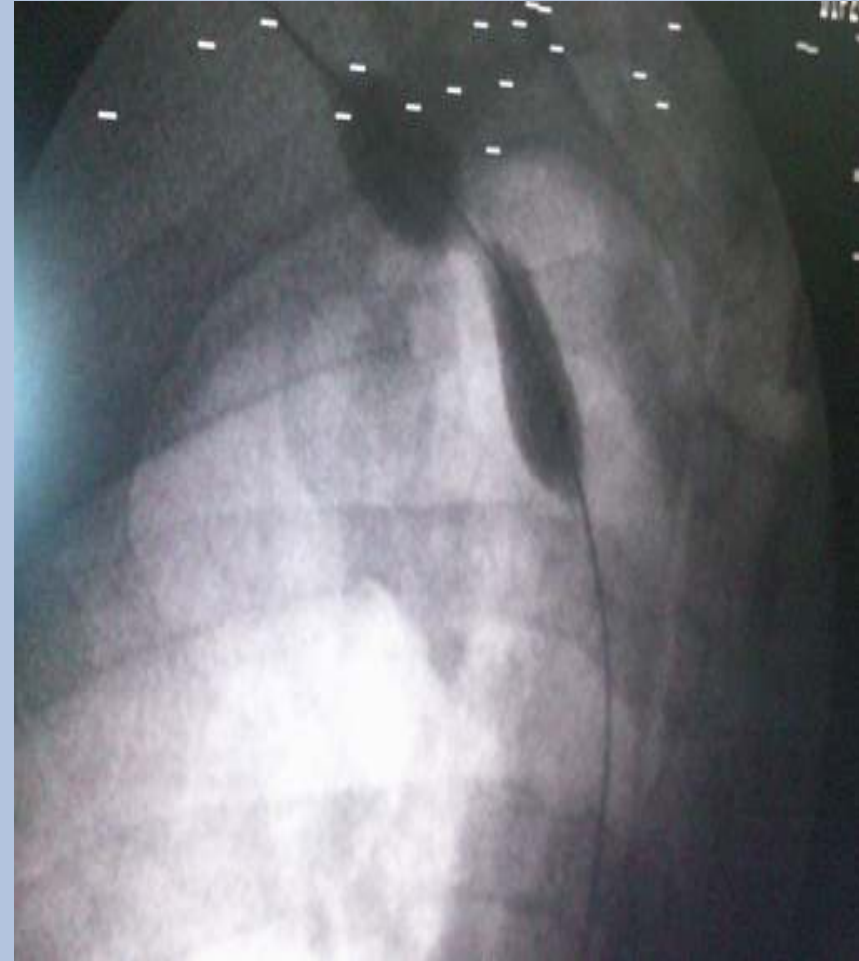complete occlusion with a about one cm distance



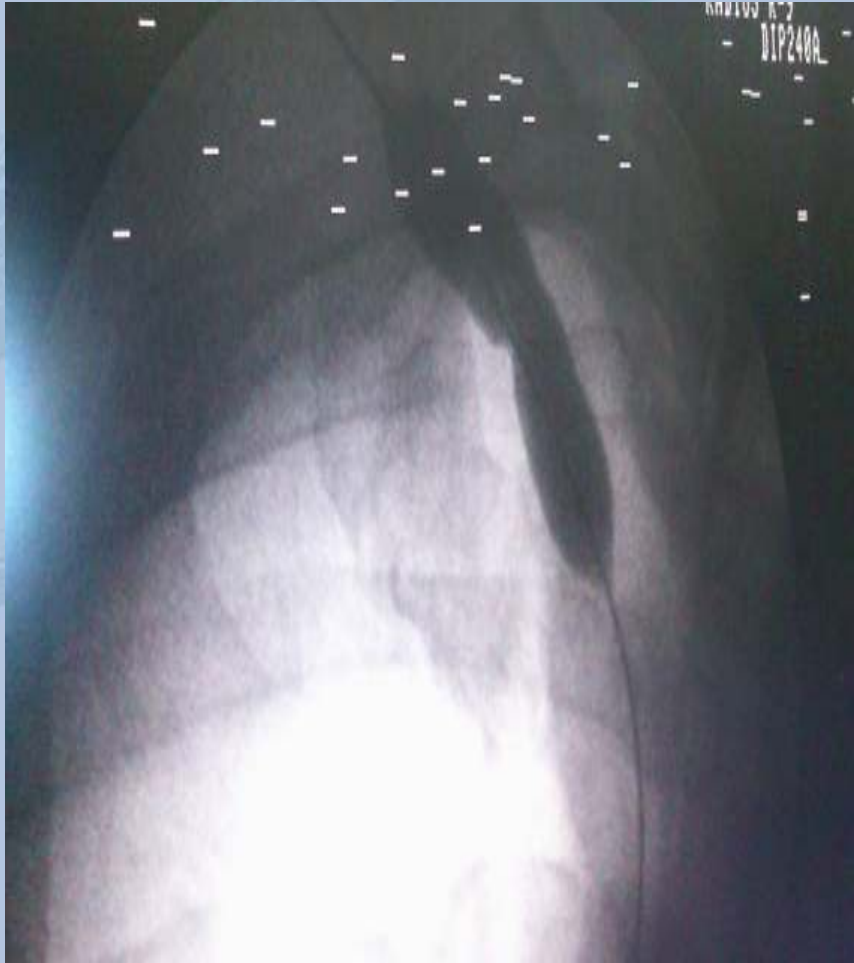gradual penetration through the occlusion



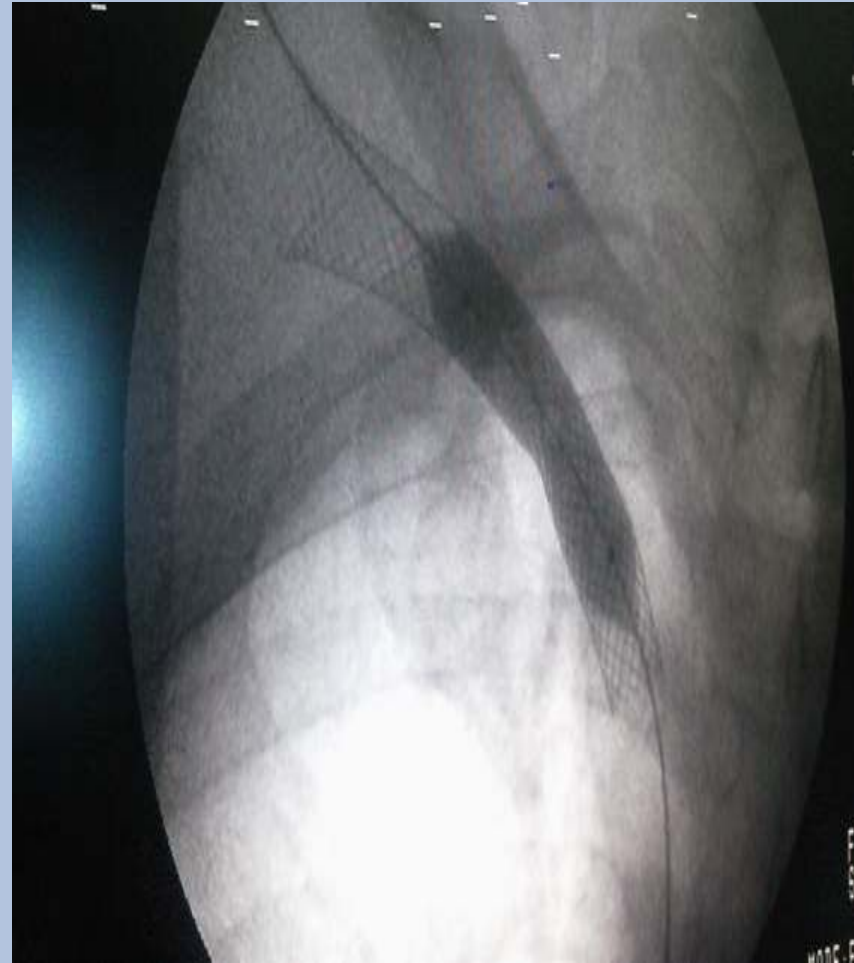successful crossing of the lesion



Balloon dilatation with waisting

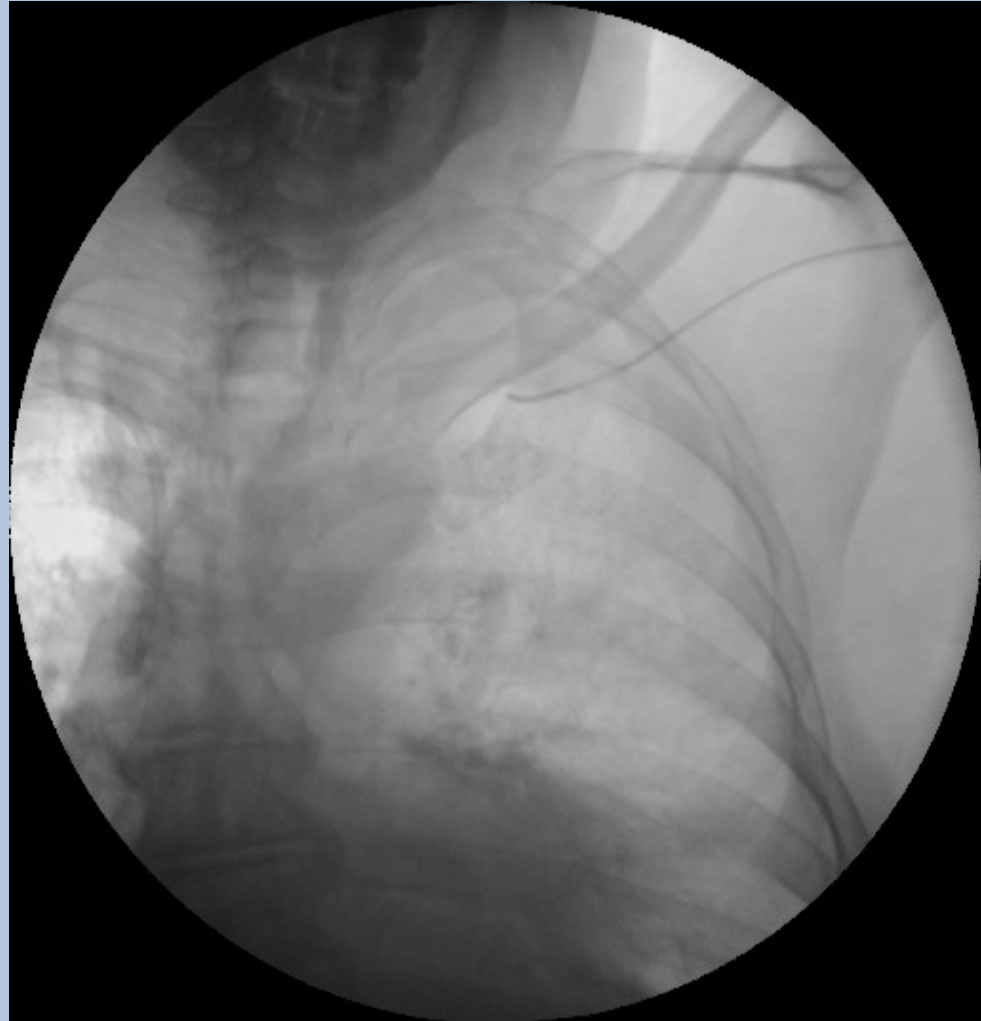
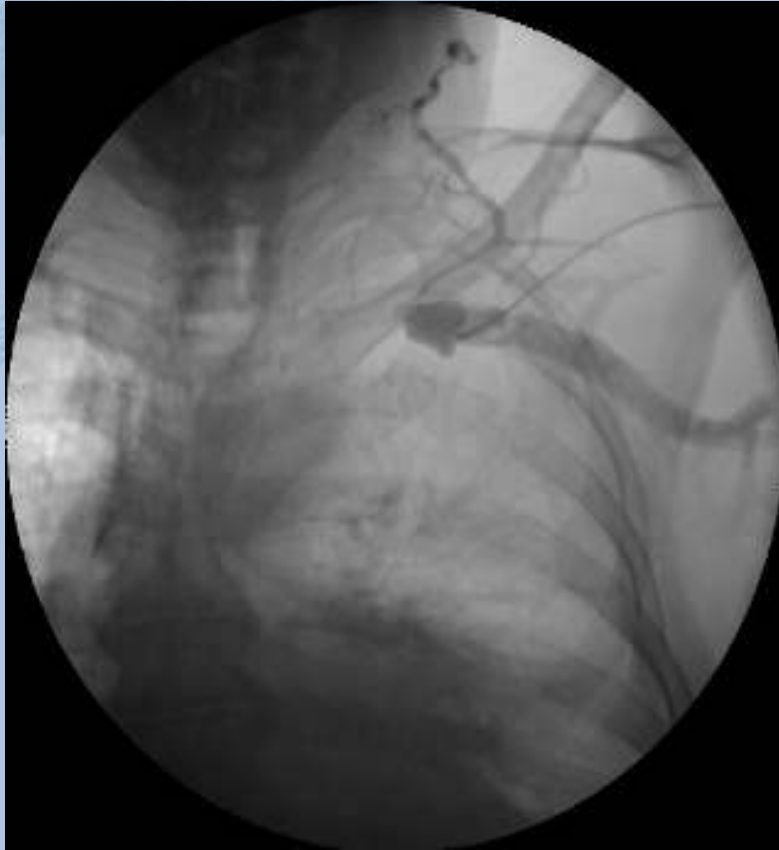


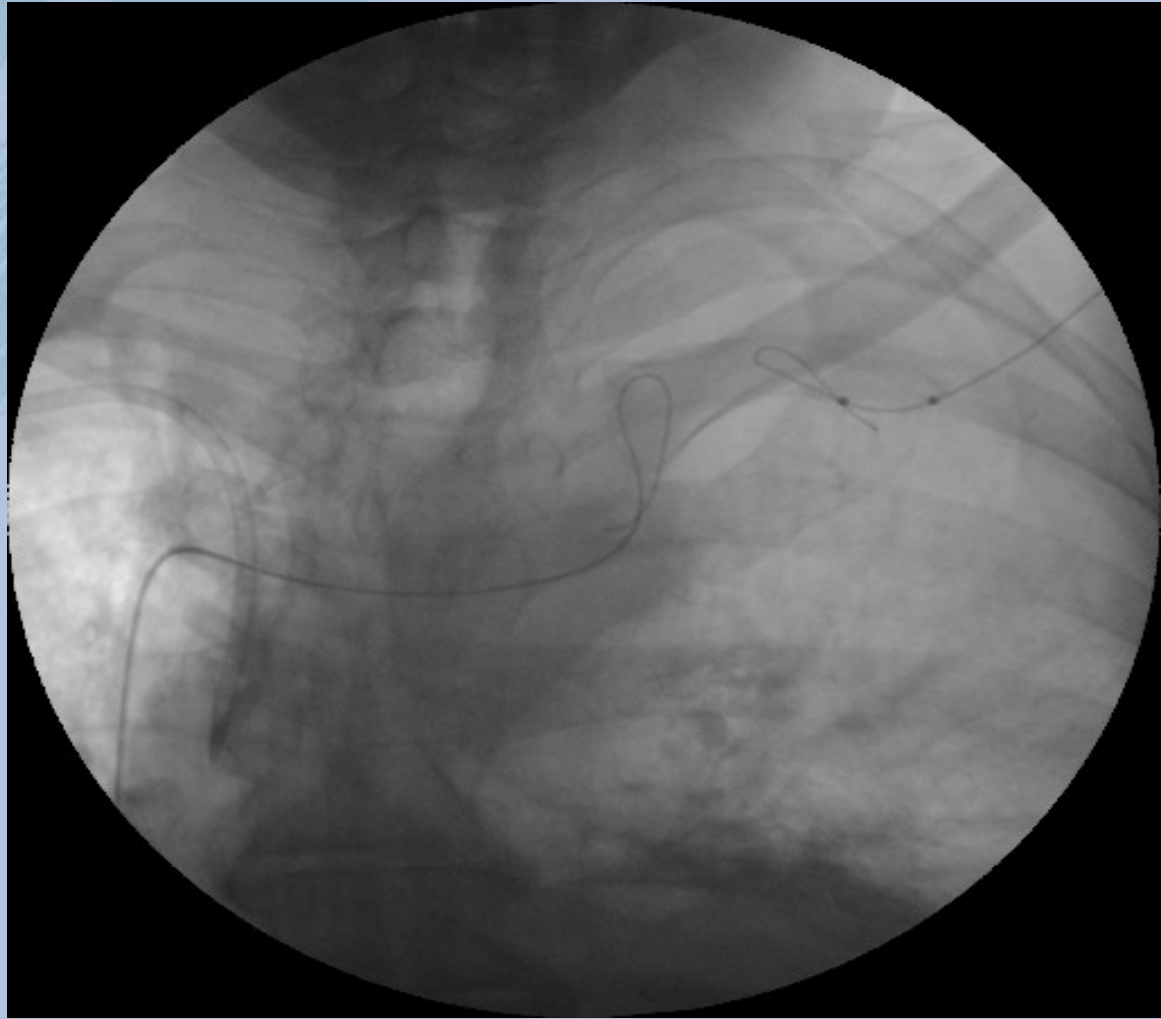
complete Balloon dilatation

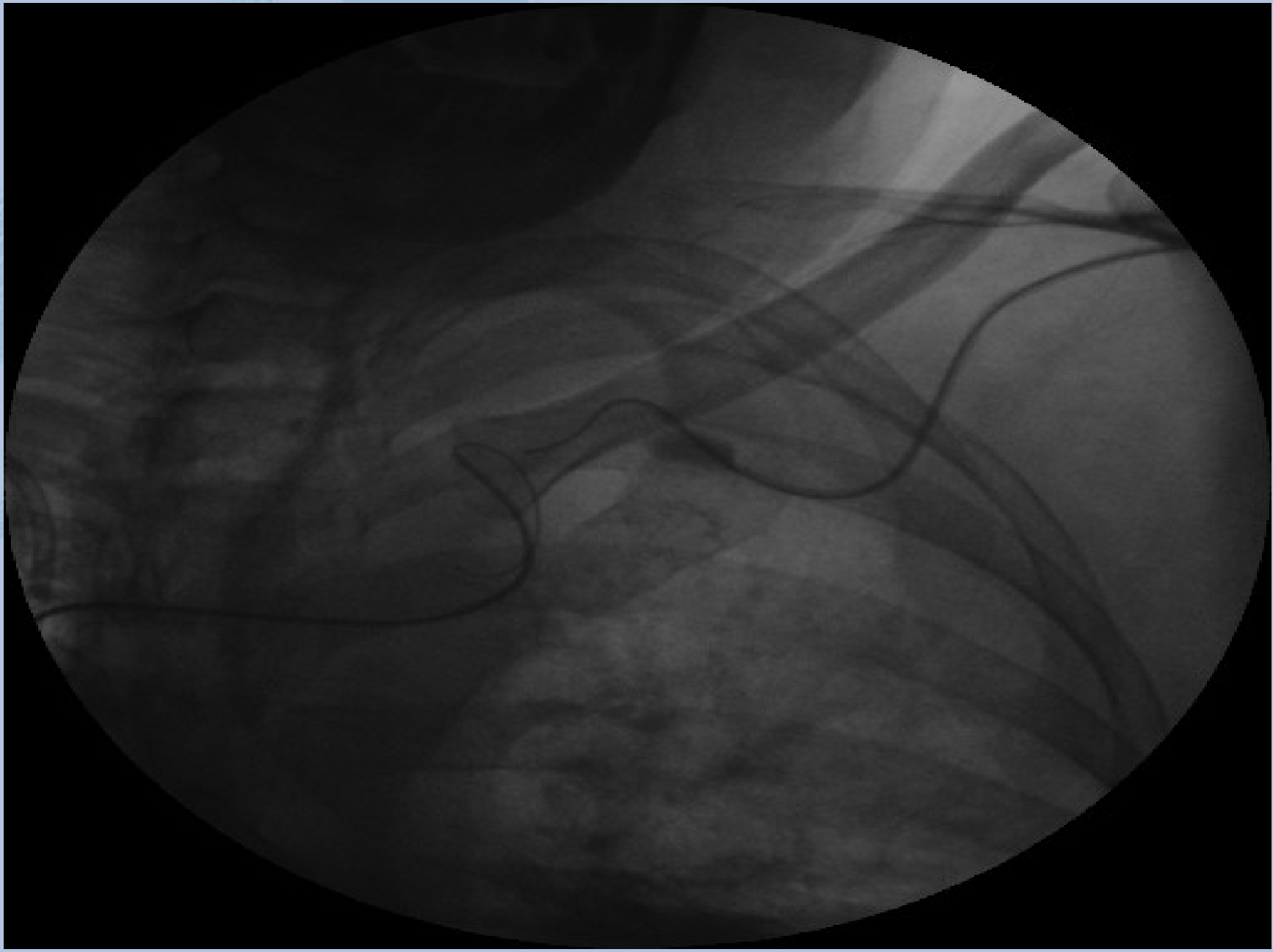


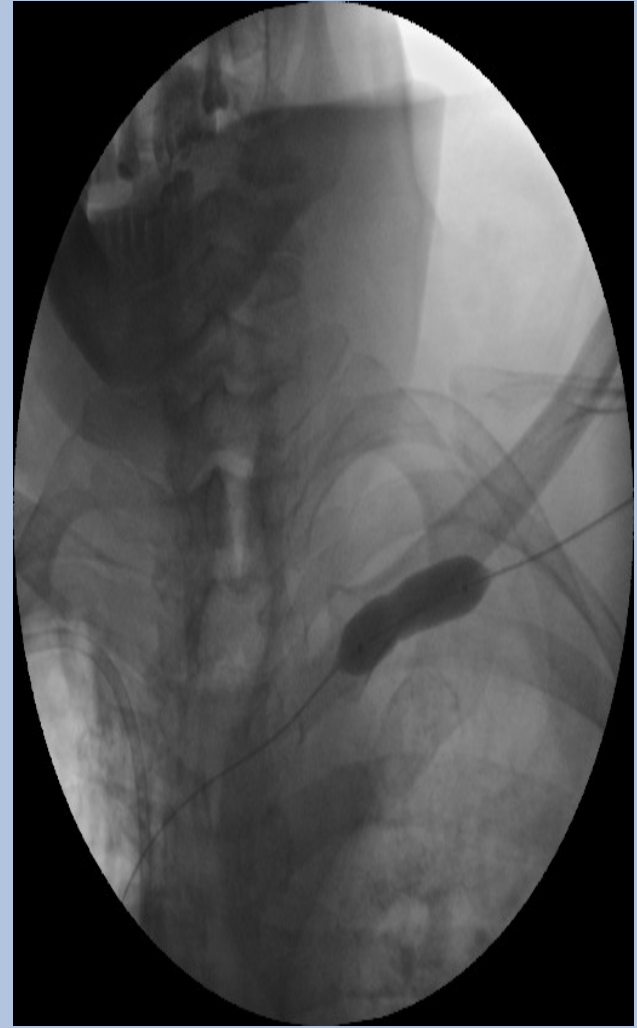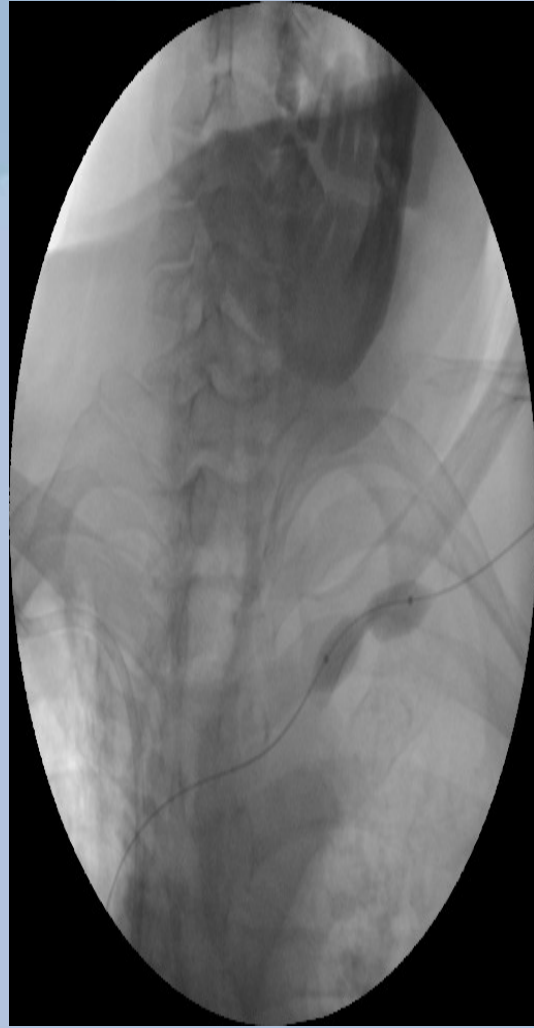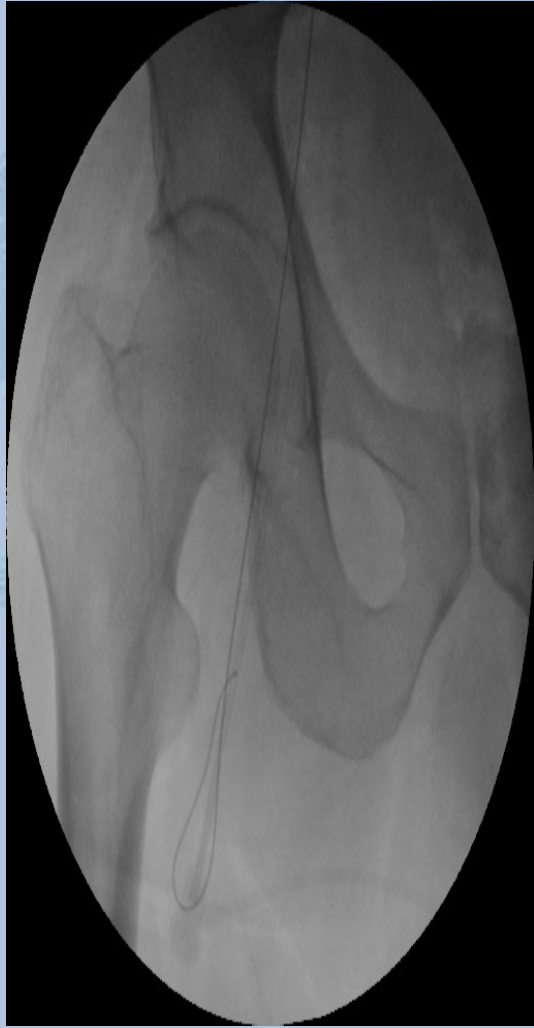stent placed through the occluded segment

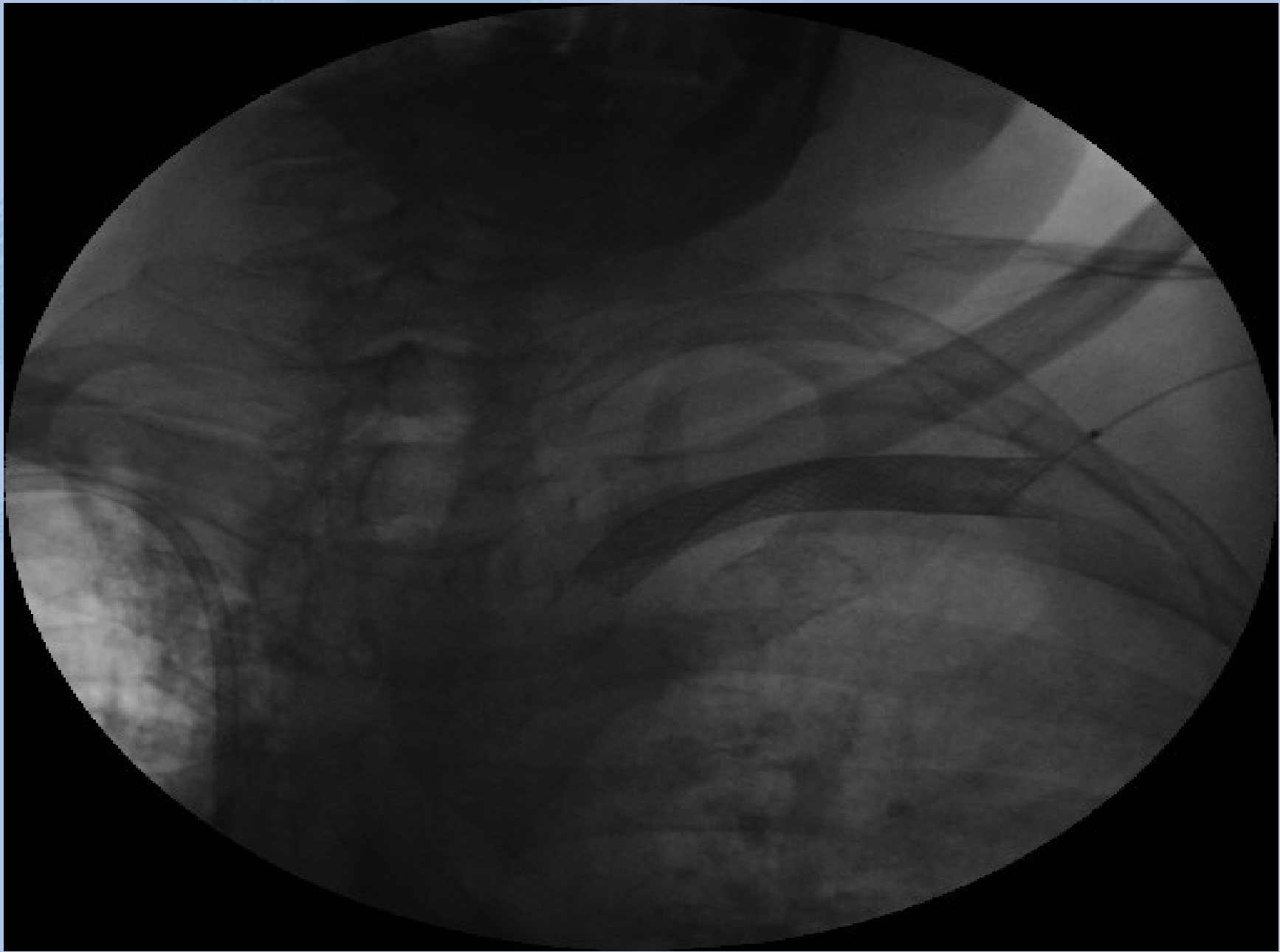
Complete LT subclav occlusion

















Long-term outcomes of primary angioplasty and primary stenting of central venous stenosis in hemodialysis patients

Andrew M. Bakken, MD,^a Clinton D. Protack, BS,^a Wael E. Saad, MD,^b
David E. Lee, MD,^b David L. Waldman, MD, PhD,^b and Mark G. Davies, MD, PhD,^{a,b} Rochester, NY

Conclusions: Endovascular therapy with PTA or PTS for central venous stenosis is safe, with low rates of technical failure. Multiple additional interventions are the rule with both treatments. Although neither offers truly durable outcomes, PTS does not improve on the patency rates more than PTA and does not add to the longevity of ipsilateral hemodialysis access sites. (J Vasc Surg 2007;45:776-83.)



Don't worry, I'll find a good site soon.

اضربك فين مافيش في وشك
مكان



vascular surgeon

CKD Patient



Thank You